



Epidemiological study of hypertensive retinopathy in the primary care setting: Retrospective cross-sectional review of retinal photographs

Lap-kin Chiang¹, Michael K.C. Yau¹, Cheuk-wai Kam¹, Lorna V. Ng¹, Benny C.Y. Zee²

Abstract

Objective: The objective is to estimate the prevalence and grading of hypertensive retinopathy in the primary care setting; examine the patient characteristics associated with hypertensive retinopathy; and examine the association of hypertensive retinopathy and other hypertension complications.

Methods: This is a retrospective cross-sectional study. Subjects included adult hypertensive patients with available and gradable retinal photographs.

Results: Two hundred fifty-six male hypertensive patients (34.3%) and 491 female hypertensive patients (65.7%) were included. The average duration of hypertension was 7.2 years, and 49.8% and 41.2% of patients were taking one or two antihypertensive medications respectively. Among 1491 qualified retinal photographs (744 right eye and 747 left eye), 24.9%, 62.6%, and 12.5% were classified as showing normal, mild, and moderate hypertensive retinopathy respectively. The three commonest retinal signs were generalized or focal arteriolar narrowing (650 cases, 43.6%), hard exudates (168 cases, 11.3%), and opacity (copper or silver wiring) of the arteriolar wall (166 cases, 11.1%). Patients older than 61 years, having hypertension for more than 15 years, or taking three or more antihypertensive medications were significantly associated with hypertensive retinopathy ($P < 0.05$).

Conclusion: In a primary care clinic in Hong Kong, 77.1% of hypertensive patients had hypertensive retinopathy. Advanced hypertensive retinopathy was the commonest target organ damage for hypertensive patients in a primary care clinic.

Keywords: Hypertensive retinopathy; retinal photograph; primary care

1. Family Medicine and General Outpatient Department, Kwong Wah Hospital, Hospital Authority, Hong Kong, China

2. The Jockey Club School of Public Health and Primary Care, The Chinese University of Hong Kong, Hong Kong, China

CORRESPONDING AUTHOR:
Lap-kin Chiang, MBChB (CUHK), MSc (CUHK), MFM (Monash)

Family Medicine and General Outpatient Department, Kwong Wah Hospital, 1/F, Tsui Tsin Tong Outpatient Building, Kwong Wah Hospital, 25 Waterloo Road, Mongkok, Hong Kong, China

E-mail: chialk@ha.org.hk

Received 14 March 2016;

Accepted 21 April 2016

Introduction

Hypertension remains a key risk factor for cardiovascular disease, the greatest cause of morbidity and mortality worldwide. Poorly controlled hypertension results in damage to the retinal microcirculation, and therefore recognition of hypertensive retinopathy (HTR) may be important in cardiovascular risk stratification for hypertensive individuals [1]. Evidence from studies showed that retinopathy

signs were related to the risk of stroke, including incident clinical stroke, ischemic stroke, and subclinical silent lacunar infarct [2–7]. The prevalence or incidence rate of various retinal microvascular lesions of in between 2% and 51% have been reported by previous studies [2, 8–11]. Various studies have shown that retinal microvascular changes can be reliably documented by retinal photographs [8, 9, 12–14].



The Joint National Committee on Prevention, Detection, Evaluation, and Treatment of High Blood Pressure indicates retinopathy as target organ damage [15]. The WHO–International Society of Hypertension [16], the British Hypertension Society guidelines [17], and the European Society of Hypertension–European Society of Cardiology guideline [18] indicate HTR grades III and IV as target organ damage.

In contrast to diabetic retinopathy, there is no widely accepted classification or definition of HTR [19]. International management guidelines are not consistent in this respect [19]. The strongest evidence for the usefulness of HTR for risk stratification is based on its association with cardiovascular outcomes such as stroke and myocardial infarction [20]. Epidemiological data on HTR were lacking in the primary care setting. This study aimed to estimate the prevalence and grading of HTR in the primary care setting, to examine the patient characteristics associated with HTR, and to examine the association of HTR and other hypertension complications.

Methods

This is a retrospective cross-sectional survey; see the Appendix for the study flowchart. All hypertensive patients who had completed hypertension complication screening during the period from January 1, 2010 to December 31, 2013 at one regional primary care clinic in Hong Kong were included. There were approximately 7000 hypertensive patients being treated by the clinic during the study period, and they were arranged for complication screening in a triennial cycle. HTR was examined by use of a direct

ophthalmoscope by a clinician or by retinal photographs. Retinal photographs were taken by a retinal photo camera (model Topcon TRC-NW8) at resolution of 3216×2136 after pupil dilation. Hypertensive patients with available and gradable retinal photographs were recruited, whereas patients with the comorbidity of diabetes mellitus or patients whose retinal photographs were either lost or of poor quality for interpretation were excluded.

Outcome measures

Relevant data – namely, smoking status, number of years diagnosed hypertension, number of antihypertensive agents, comorbidities, and the summary of complication screening were retrieved from the patient computerized medical system. All retinal photographs were reviewed and graded by two researchers independently. The researchers had completed training in retinal photograph viewing and grading. Retinal findings were recorded as an exact description based on the visual impression of the researchers and then graded according to the classification proposed by Wong and Mitchell [20]. If a discrepancy in grading existed between the two researchers, a consensus would be reached after a group discussion by at least three researchers. All retinal photographs (both available right and left eyes) were included for grading. The eye with higher severity of grading determined the grade of HTR for the patient.

Definition of HTR

The definition of HTR was based on the Wong and Mitchell [20] classification (Table 1).

Table 1. Wong and Mitchell classification of hypertensive retinopathy

Grade of retinopathy	Retinal signs	Systemic associations
None	No detectable signs	None
Mild	Generalized arteriolar narrowing, focal arteriolar narrowing, arteriovenous nicking, opacity (copper wiring or silver wiring) of arteriolar wall, or a combination of these signs	Modest association with risk of clinical stroke, subclinical stroke, coronary heart disease, and death
Moderate	Hemorrhage (blot, dot, or flame shaped), microaneurysm, cotton wool spot, hard exudate, or a combination of these signs	Strong association with risk of clinical stroke, subclinical stroke, cognitive decline, and death from cardiovascular causes
Malignant	Signs of moderate retinopathy plus swelling of the optic disc	Strong association with death



Statistical analysis

Descriptive statistics including the mean, standard deviation (SD), frequency, and percentage were used to summarize the characteristics of the variables. Descriptive information for each of the explanatory variables are presented. Bivariate association of the variables with HTR was assessed by the chi-square test for categorical variables. Multivariate analysis with logistic regression was applied to examine the predictive factors. A *P* value of less than 0.05 was considered as significant. Data analysis was performed with the Statistical Package for the Social Sciences (version 21.0, SPSS, United States).

Research ethics

The study was approved by the Kowloon West Cluster Research Ethics Committee of the Hong Kong Hospital Authority.

Results

Two hundred fifty-six male hypertensive patients (34.3%) and 491 female hypertensive patients (65.7%) were included, with a mean (SD) age of 59.2 (8.6) years (Table 2). The average duration of hypertension was 7.2 years, and 49.8% and 41.2% of patients were taking one or two antihypertensive medications respectively. The three leading associated comorbidities were dyslipidemia (53.3%), obesity (44.3%), and a history of stroke (3.9%). The mean (SD) blood pressure was 128.2 (11.5)/75.3 (7.7) mm Hg.

Hypertensive retinopathy

One thousand four hundred ninety-one retinal photographs (744 right eye and 747 left eye) were qualified for classification (Table 3). Among these 24.9%, 62.6%, and 12.5% were classified as showing normal, mild, and moderate HTR respectively. No severe retinopathy was reported. The three commonest retinal signs were generalized or focal arteriolar narrowing (650 cases, 43.6%), hard exudates (168 cases, 11.3%), and opacity (copper wiring or silver wiring) of the arteriolar wall (166 cases, 11.1%). No swelling of the optic disc was reported. Overall, 576 patients (77.1%) had any HTR and 130 patients (17.4%) had moderate HTR.

Patient characteristics associated with HTR

Table 2 illustrates that 77.1% of patients (576 of 747) had HTR of any severity. Bivariate analysis with the chi-square test

revealed that hypertensive patients older than 61 years, having hypertension for more than 15 years, or taking three or more antihypertensive medications were negatively associated with HTR. By means of univariate logistic regression analysis, diastolic blood pressure significantly predicted HTR (*P*=0.025).

Multivariate analyses by a logistic regression procedure were applied to determine the patient characteristics associated with HTR. Factors including age, duration of hypertension, number of antihypertensive drugs, and diastolic blood pressure were included for analysis. The final fitted model revealed that patient age was statistically significantly associated with HTR. The odds ratio was 0.96 (95% confidence interval 0.94–0.98, *P*<0.001).

Patient characteristics associated with moderate HTR

Table 4 summarizes the patient characteristics associated with moderate HTR. One hundred thirty patients (17.4%) had moderate HTR. Advanced patient age, longer duration of hypertension, and taking a greater number of antihypertensive agents were statistically significantly associated with moderate HTR. Both systolic and diastolic blood pressure were associated with moderate HTR.

Multivariate analyses by a logistic regression procedure were applied to determine the patient characteristics associated with moderate HTR. Factors including age, duration of hypertension, and number of antihypertensive drugs were included for analysis. The final fitted model revealed that patient age was statistically significantly associated with moderate HTR. The odds ratio was 1.04 (95% confidence interval 1.02–1.06, *P*=0.001).

Hypertension complications

As illustrated in Table 5, the hypertension complications were reported as either target organ damage or associated clinical conditions according to the European Society of Hypertension–European Society of Cardiology guidelines [18]. The leading three complications or target organ damage were advanced HTR (17.4%), heart disease (7.1%), and cerebrovascular disease (3.9%).

Discussion

This cross-sectional study revealed that HTR was prevalent among hypertensive patients in a primary care setting.



Table 2. Patient demographics and association with hypertensive retinopathy

	Total no. (%)/mean (SD)	HTR no. (%)	P	OR	95% CI
Study population	747	576 (77.1%)			
Sex					
Female	491 (65.7%)	370 (75.4%)	–	1.00	
Male	256 (34.3%)	206 (80.5%)	0.114	1.35	0.87–1.74
Age, years					
Mean (SD)*	59.2 (8.6)	–	<0.001	0.96	0.94–0.98
≤50	115 (15.4%)	97 (84.3%)	–	1.00	–
51–60	285 (38.1%)	232 (81.4%)	0.485	0.81	0.45–1.46
61–70	283 (37.9%)	210 (74.2%)	0.029	0.53	0.30–0.94
≥71	64 (8.6%)	37 (57.8%)	<0.001	0.25	0.13–0.52
Duration of HT, years					
Mean (SD)	7.21 (5.4)	–	0.945	1.00	0.97–1.03
≤5	380 (50.9%)	309 (81.3%)	–	1.00	–
6–10	214 (28.6%)	161 (75.2%)	0.080	0.70	0.47–1.05
11–15	102 (13.7%)	79 (77.5%)	0.382	0.79	0.46–1.34
≥16	51 (6.8%)	27 (52.9%)	<0.001	0.26	0.14–0.47
No. of antihypertensive drugs					
0 (diet control)	7 (0.9%)	–	–	–	–
1	372 (49.8%)	303 (81.5%)	–	1.00	–
2	308 (41.2%)	233 (75.6%)	0.065	0.71	0.49–1.02
≥3	60 (8.1%)	35 (58.3%)	<0.001	0.32	0.18–0.57
Smoking status					
Nonsmoker	629 (84.2%)	480 (76.3%)	–	1.00	–
Smoker (ex-smoker and current smoker)	118 (15.8%)	96 (81.4%)	0.231	1.36	0.82–2.23
Associated comorbidity					
Hyperlipidemia	398 (53.3%)	317 (79.6%)	0.095	1.34	0.95–1.89
Arrhythmia	4 (0.5%)	2 (50.0%)	–	–	–
CVA	29 (3.9%)	23 (79.3%)	0.773	1.14	0.46–2.86
IHD	18 (2.4%)	11 (61.1%)	0.102	0.46	0.17–1.20
CHF	2 (0.3%)	–	–	–	–
Chronic kidney disease	12 (1.6%)	9 (75.0%)	0.861	0.89	0.24–3.32
Proteinuria	5 (0.7%)	4 (80.0%)	0.877	1.19	0.13–10.71
LVH	68 (9.1%)	57 (83.8%)	0.167	1.60	0.82–3.12
PVD	2 (0.3%)	–	–	–	–
OSA	11 (1.5%)	10 (90.9%)	0.272	3.00	0.38–23.63
Obesity (BMI > 25 kg/m ²)	331 (44.3%)	258 (77.9%)	0.713	1.07	0.76–1.51
BP, mm Hg					
Systolic BP*	128.2 (11.5)	–	0.790	1.00	0.98–1.01
Diastolic BP*	75.3 (7.7)	–	0.025	1.03	1.00–1.05



Table 2 (continued)

	Total no. (%) / mean (SD)	HTR no. (%)	<i>P</i>	OR	95% CI
Fasting glucose, mmol/L					
Mean (SD)	5.21 (0.38)	–	–	–	–
LDL cholesterol, mmol/L					
Mean (SD)	3.35 (0.78)	–	–	–	–

BMI, body mass index; BP, blood pressure; CHF, congestive heart failure; CI, confidence interval; CVA, cerebrovascular accident; HT, hypertension; HTR, hypertensive retinopathy; IHD, ischemic heart disease; LDL, low-density lipoprotein; LVH, left ventricular hypertrophy; OR, odds ratio; OSA, obstructive sleep apnea; PVD, peripheral vascular disease; SD, standard deviation.

*Obtained by means of univariate logistic regression analysis, while other categorical outcomes were obtained by chi-square analysis.

Table 3. Retinal photography outcomes

	Right eye	Left eye	Total	Total (%)
No. of retinal photographs for grading	744	747	1491	
Grade of retinopathy				
Normal	193	179	372	24.9
Mild	460	473	933	62.6
Moderate	91	95	186	12.5
Severe	0	0	0	0
Signs of retinopathy				
Generalized arteriolar narrowing	263	259	522	35.0
Focal arteriolar narrowing	64	64	128	8.6
Arteriovenous nicking	71	82	153	10.3
Opacity of arteriolar wall	80	86	166	11.1
Hemorrhage	7	16	23	1.5
Microaneurysm	1	1	2	0.1
Cotton wool spot	2	0	2	0.1
Hard exudate	82	86	168	11.3
Swollen optic disc	0	0	0	0

Some retinal photographs documented more than one retinal sign.

Advanced HTR (moderate or malignant retinopathy) was the commonest hypertensive target organ damage.

'Hypertensive retinopathy' (HTR) refers to retinal microvascular signs that develop in response to raised blood pressure [14, 21–23]. It is predictive of incident stroke, congestive heart failure, and cardiovascular mortality independently of traditional risk factors [2, 23]. The initial response to raised blood pressure is a vasoconstrictive phase, which manifests itself

clinically as generalized retinal arteriolar narrowing. The subsequent arteriosclerotic phase is characterized by hyperplasia of the tunica media, hyaline degeneration of the arteriolar wall, and intimal thickening, which manifest themselves clinically as vessel attenuation, increased arteriolar reflex, arteriovenous nicking, and increased tortuosity of arterioles. With more pronounced high blood pressure, the blood–retinal barrier breaks down, resulting in exudation of blood (hemorrhage), lipids



Table 4. Patient demographics and association with moderate hypertensive retinopathy

	Total no. (%) / mean (SD)	Moderate HTR no. (%)	P	OR	95% CI
Study population	747	130 (17.4%)			
Sex					
Female	491 (65.7%)	82 (16.7%)	–	1.00	
Male	256 (34.3%)	48 (18.8%)	0.483	1.15	0.78–1.71
Age, years					
Mean (SD)*	59.2 (8.6)	–	<0.001	1.04	1.02–1.07
≤50	115 (15.4%)	8 (7.0%)	–	1.00	–
51–60	285 (38.1%)	43 (15.1%)	0.027	2.38	1.08–5.23
61–70	283 (37.9%)	63 (22.3%)	<0.001	3.83	1.77–8.28
>71	64 (8.6%)	16 (25.0%)	0.001	4.46	1.79–11.23
Duration of HT					
Mean (SD)	7.21 (5.4)	–	0.046	1.03	1.00–1.07
≤5	380 (50.9%)	43 (11.3%)	–	1.00	–
6–10	214 (28.6%)	41 (19.2%)	0.008	1.86	1.17–2.96
11–15	102 (13.7%)	36 (35.3%)	<0.001	4.28	2.55–7.16
≥16	51 (6.8%)	10 (19.6%)	0.090	1.91	0.89–4.09
No. of antihypertensive drugs					
0 (diet control)	7 (0.9%)	–	–	–	–
1	372 (49.8%)	42 (11.3%)	–	1.00	–
2	308 (41.2%)	71 (23.1%)	<0.001	2.35	1.55–3.57
≥3	60 (8.1%)	16 (26.7%)	0.001	2.86	1.48–5.51
Smoking status			–		
Nonsmoker	629 (84.2%)	112 (17.8%)	–	1.00	–
Smoker (ex-smoker and current smoker)	118 (15.8%)	18 (15.3%)	–	0.83	0.48–1.43
Associated comorbidity					
Hyperlipidemia	398 (53.3%)	69 (17.3%)	0.844	0.96	0.66–1.41
Arrhythmia	4 (0.5%)	0	–	–	–
CVA	29 (3.9%)	4 (13.8%)	0.601	0.75	0.26–2.20
IHD	18 (2.4%)	2 (11.1%)	0.477	0.59	0.13–2.58
CHF	2 (0.3%)	0	–	–	–
Chronic kidney disease	12 (1.6%)	1 (8.3%)	0.403	0.43	0.06–3.34
Proteinuria	5 (0.3%)	0	–	–	–
LVH	68 (9.1%)	11 (16.2%)	0.780	0.91	0.46–1.78
PVD	2 (0.3%)	0	–	–	–
OSA	11 (1.5%)	1 (9.1%)	0.164	0.47	0.06–3.71
Obesity (BMI > 25 kg/m ²)	331 (44.3%)	58 (17.5%)	0.963	1.01	0.69–1.48
BP, mm Hg					
Systolic BP*	128.2 (11.5)	–	0.826	1.00	0.99–1.02
Diastolic BP*	75.3 (7.7)	–	0.161	0.98	0.96–1.01



Table 4 (continued)

	Total no. (%) / mean (SD)	Moderate HTR no. (%)	<i>P</i>	OR	95% CI
Fasting glucose, mmol/L					
Mean (SD)	5.18 (0.35)	–	–	–	–
LDL cholesterol, mmol/L					
Mean (SD)	3.29 (0.79)	–	–	–	–

BMI, body mass index; BP, blood pressure; CHF, congestive heart failure; CI, confidence interval; CVA, cerebrovascular accident; HT, hypertension; HTR, hypertensive retinopathy; IHD, ischemic heart disease; LDL, low-density lipoprotein; LVH, left ventricular hypertrophy; OR, odds ratio; OSA, obstructive sleep apnea; PVD, peripheral vascular disease; SD, standard deviation.

*Obtained by means of univariate logistic regression analysis, while other categorical outcomes were obtained by chi-square analysis.

Table 5. Hypertension target organ damage or associated conditions

	Number	Percentage
Left ventricular hypertrophy	68	9.1
Microalbuminuria	5	0.7
Cerebrovascular disease	29	3.9
Heart disease	53	7.1
Renal disease	12	1.6
Peripheral vascular disease	2	0.3
Advanced hypertensive retinopathy	130	17.4

Advanced hypertensive retinopathy includes moderate and malignant retinopathy.

(hard exudates), and subsequent ischemia of nerve-fiber layers (cotton wool spots). In the setting of severely high blood pressure, raised intracranial pressure and concomitant optic nerve ischemia can lead to disc swelling (papilledema).

The prevalence of HTR in our study was remarkably higher than in previous studies; that is, 2–15% [8–11]. However, those were population-based studies including individuals with or without a history of hypertension. In the study by Ong et al. [2] involving hypertensive participants, the prevalence of mild HTR was 46.6% and that of moderate HTR was 5.1%. The higher prevalence in the more recent studies was probably due to the higher sensibility of photography as compared with clinical ophthalmoscopy for detecting certain signs of retinopathy [20].

Our study revealed that patient age, duration of hypertension, and number of antihypertensive medications taken were negatively associated with any HTR; however, those factors

were positively associated with moderate HTR. The exact reasons for this reverse relationship are not clear. Findings from the Atherosclerosis Risk in Communities Study [24], the Blue Mountains Eye Study [9], and the Beaver Dam Eye Study [8] indicate that the pathogenesis of retinal arteriolar changes (focal and generalized arteriolar narrowing, and arteriovenous nicking) was distinct from that of severer signs of HTR (hemorrhage, hard exudates, or cotton wool spots). Evidence revealed that generalized retinal arteriolar narrowing (i.e., graded as mild HTR) appeared to be more prominent in younger individuals than in older individuals with similar severity of hypertension [14]. Clinical trials showed that the signs of HTR regressed with good control of blood pressure [25, 26]. It was also suggested that antihypertensive medication that had direct beneficial effects on the microvascular structure (e.g., angiotension-converting enzyme inhibitors) would reduce the damage caused by retinopathy beyond the reduction effected by lowered blood pressure [20]. The participants in our study were all hypertensive patients, who had an average of 7.2 years of hypertension, and 99.1% were taking antihypertensive medications. However, they achieved good hypertension control, with a mean blood pressure of 128.2/75.3 mm Hg. It is probable that the high proportion of mild HTR (i.e. 62.6%) might be reduced with time after attainment of good control of blood pressure.

Hypertension is prevalent in Hong Kong. The Population Health Survey 2003/2004 of the Department of Health revealed that approximately 27% of the population aged 15 years or older had increased blood pressure [27]. Among those in whom hypertension had been diagnosed, 70% were prescribed



blood-pressure-lowering medication, but only about 40% of those receiving treatment attained control of their blood pressure [28]. Worldwide, hypertension awareness, treatment, and control remain less than optimal [29]. Recognition of HTR may be important in cardiovascular risk stratification and in prediction of other cardiovascular complications of hypertensive patients [1, 2]. Physicians should undertake more vigilant monitoring of the cardiovascular risk in patients with mild retinopathy, or adopt an aggressive approach to risk reduction in patients with moderate retinopathy. Urgent antihypertensive treatment and ophthalmologist care should be initiated for patients who have severe retinopathy [20].

As stated by Wong and Mitchell [20], the data from HTR studies might support the development of a photographic classification of HTR that would be similar to the photographic grading of diabetic retinopathy. Secondly, the information will also promote additional prospective studies that aim to demonstrate an independent association of HTR with various cardiovascular outcomes. This information will be important when one is formulating a clinical protocol, planning screening services, or projecting cost, especially in the face of an escalating awareness of hypertension care in our local community.

This study has limitations. It is a retrospective survey, not all hypertensive patients have eligible retinal photographs, and the acquisition of retinal photographs is ordered by all physicians in the department; therefore a patient selection bias cannot be excluded. This study involved patients from one primary care clinic only, and it is uncertain whether this study group represents the whole patient population in the primary care setting.

Conclusion

In a primary care clinic in Hong Kong, 77.1% hypertensive patients had HTR. Advanced HTR was the commonest target organ damage for hypertensive patients in the primary care clinic. Multivariate analysis revealed that patient age was the only factor significantly associated with HTR.

Acknowledgment

The authors thank the Hong Kong College of Family Physicians for supporting this research.

Conflict of interest

The authors declare no conflict of interest.

Funding

Hong Kong College of Family Physicians Research Seed Fund.

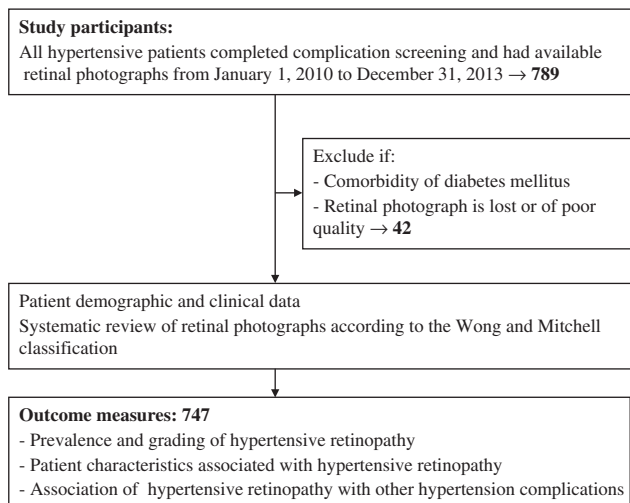
References

1. Chatterjee S, Chattopadhyaya S, Hope-Ross M, Lip PL. Hypertension and the eye: changing perspectives. *J Hum Hypertens* 2002;16(10):667–75.
2. Ong YT, Wong TY, Klein R, Klein BEK, Mitchell P, Sharrett AR, et al. Hypertensive retinopathy and risk of stroke. *Hypertension* 2013;62(4):706–11.
3. Wong TY, Klein R, Nieto FJ, Klein BEK, Sharrett AR, Meurer SM, et al. Retinal microvascular abnormalities and 10-year cardiovascular mortality: a population-based case-control study. *Ophthalmology* 2003;110(5):933–40.
4. Mitchell P, Wang JJ, Wong TY, Smith W, Klein R, Leeder SR. Retinal microvascular signs and risk of stroke and stroke mortality. *Neurology* 2005;65(7):1005–9.
5. Witt N, Wong TY, Hughes AD, Chaturvedi N, Klein BEK, Evans R, et al. Abnormalities of retinal microvascular structure and risk of mortality from ischaemic heart disease and stroke. *Hypertension* 2006;47(5):975–81.
6. Wong TY, Klein R, Sharrett AR, Couper DJ, Klein BEK, Liao DP, et al. Cerebral white matter lesions, retinopathy, and incident clinical stroke. *J Am Med Assoc* 2002;288(1):67–74.
7. Yatsuya H, Folsom AR, Wong TY, Klein R, Klein BEK, Sharrett AR. Retinal microvascular abnormalities and risk of lacunar stroke: Atherosclerosis Risk in Community Study. *Stroke* 2010;41(7):1349–55.
8. Klein R, Klein BEK, Moss SE. The relation of systemic hypertension to changes in the retinal vasculature: the beaver dam eye study. *Trans Am Ophthalmol Soc* 1997;95:329–48.
9. Wong JJ, Mitchell P, Leung H, Rohtchina E, Wong TY, Klein R. Hypertensive retinal wall signs in a general older population: the blue mountains eye study. *Hypertension* 2003;42(4):534–41.
10. Wong TY, Klein R, Klein BE, Meurer SM, Hubbard LD. Retinal vessel diameter and their associations with age and blood pressure. *Invest Ophthalmol Vis Sci* 2003;44(11):4644–50.
11. Wong TY, Hubbard LD, Klein R, Marino EK, Kronmal R, Sharrett AR, et al. Retinal microvascular abnormalities and blood pressure in older people: the cardiovascular health study. *Br J Ophthalmol* 2002;86(9):1007–13.
12. Couper DJ, Klein R, Hubbard L, Wong TY, Sorlie PD, Cooper LS, et al. Reliability of retinal photographs in the assessment of retinal microvascular characteristics: the Atherosclerosis Risk in Communities Study. *Am J Ophthalmol* 2002;133(1):78–88.



13. Sharrett AR, Hubbard LD, Cooper LS, et al. Retinal arteriolar diameters and elevated blood pressure. The Atherosclerosis Risk in Community Study. *Am J Epidemiol* 1999;150(3):263–70.
14. Wong TY, Klein R, Klein BEK, Tielsch JM, Hubbard L, Nieto FJ. Retinal microvascular abnormalities and their relationship with hypertension, cardiovascular diseases and mortality. *Surv Ophthalmol* 2001;46(1):59–80.
15. Chobonian AV, Bakris GL, Black HR, Cushman WC, Green LA, Izzo JL, et al. Seventh report of the joint national committee on prevention, detection, evaluation, and treatment of high blood pressure. *J Hypertens* 2003;42(6):1206–52.
16. World Health Organization/International Society of Hypertension Writing Group. 2003 WHO/ISH statement on management of hypertension. *J Hypertens* 2003;21(11):1983–92.
17. Williams B, Poulter NR, Brown MJ, Davis M, McInnes GT, Potter JF, et al. British hypertension society guidelines for hypertension management 2004 (BHS-IV): summary. *BMJ* 2004;328(7440):634–40.
18. Guidelines Committee. 2013 European Society of Hypertension (ESH)/European Society of Cardiology (ESC) guidelines for the management of arterial hypertension. *J Hypertens* 2013;31(7):1281–357.
19. Grosso A, Veglio F, Porta M, Grignolo FM, Wong TY. Hypertensive retinopathy revisited: some answers, more questions. *Br J Ophthalmol* 2005;89(12):1646–54.
20. Wong TY, Mitchell P. Hypertensive retinopathy. *N Engl J Med* 2004;351(22):2310–7.
21. Wong TY, Mitchell P. The eye in hypertension. *Lancet* 2007;369(9559):425–35.
22. Sharma K, Kanaujia V, Mishra P, Agarwal R, Tripathi A. Hypertensive retinopathy. *Clin Queries Nephrol* 2013;2:136–9.
23. Handerson AD, Bruce BB, Newman NJ, Biousse V. Hypertension-related eye abnormalities and the risk of stroke. *Rev Neurol Di* 2011;8(1–2):1–9.
24. Klein R, Sharrett AR, Klein BEK, Chambless LE, Cooper LS, Hubbard LD, et al. Are retinal arteriolar abnormalities related to atherosclerosis? The atherosclerosis risk in communities study. *Arterioscler Thromb Vasc Biol* 2000;20(6):1644–50.
25. Bock KD. Regression of retinal vascular changes by antihypertensive therapy. *Hypertension* 1984;6(6 Pt 2):III158–62.
26. Dahlof B, Stenkula S, Hansson L. Hypertensive retinal vascular changes: relationship to left ventricular hypertrophy and arteriolar changes before and after treatment. *Blood Press* 1992;1(1):35–44.
27. Department of Health. Report on population health survey 2003/04. Hong Kong SAR: Department of Health; 2005.
28. Centre for Health Protection, Hong Kong SAR [Internet]. Hypertension – the Preventable and Treatable Silent Killer. [accessed 2013 May 15]. Available from: www.chp.gov.hk.
29. Wolf-Marier K, Cooper RS, Kramer H, Banegas JR, Giampaoli S, Joffreset MR, et al. Hypertension treatment and control in five European countries, Canada, and the United States. *Hypertension* 2004;43(1):10–7.

Appendix



Study flowchart