

Unilateral rhinorrhoea and button battery: a case report

Geng Ju Tuang, Nik Roslina Nik Hussin, Zainal Azmi Zainal Abidin

To cite: Tuang GJ, Nik Hussin NR, Zainal Abidin ZA. Unilateral rhinorrhoea and button battery: a case report. *Fam Med Com Health* 2019;7:e000137. doi:10.1136/fmch-2019-000137

Received 11 March 2019
Revised 21 May 2019
Accepted 21 May 2019

SUMMARY

Unilateral rhinorrhoea in the paediatric age group could be an alarming sign that warrants a clinician attention. These patients are routinely brought to see general practitioner as parents may not be aware of the urgency to intervene surgically. Herein we describe a case of a toddler who presented initially to a general practitioner with unilateral nasal discharge. He was subsequently referred to the otorhinolaryngology department for unresolved rhinitis. The child was examined, and the diagnosis of an embedded foreign body was made. X-ray of the paranasal sinus unveiled an embedded button battery. An emergency endoscopic retrieval of the button battery was performed under general anaesthesia. Unfortunately, the case was complicated with a huge septal perforation.

INTRODUCTION

Button batteries are easily accessible as they powered most of our electronic devices used for our day-to-day life. Such miniature yet potentially fatal item deserves special attention for its hybrid between a foreign body and caustic agent in the upper aerodigestive tract. Children are particularly attracted and deceived by its smooth and glossy appearance. The common sites of a lodged foreign body include ear canal, nasal cavity and upper aerodigestive tract.^{1,2} Dreadful complications as a result of impacted button batteries such as oesophagopericardial fistula, oesophageal stenosis and nasal septum perforation have been described.²⁻⁴ The clinical features of an embedded button battery in the nostril are often non-specific and indifferent from the presentation of rhinitis, which imposes great difficulty in diagnosis. If the diagnosis was delayed or missed, it could potentially lead to local infection, structural destruction or septic shock. Herein, we report a case of embedded button battery in the nasal cavity which unfortunately resulted in septal perforation.

CASE PRESENTATION

A 3-year-old toddler was referred to the otorhinolaryngology department for persistent rhinitis. The parents noticed that

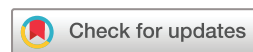he had suffered from worsening intermittent rhinorrhoea from the right nostril for the past 2 weeks despite oral antibiotics. The discharge was described as serous-purulent in consistency and foul smelling. Further history revealed neither fever nor recent sick contact. His medical and allergic history was unremarkable.

The toddler remained active with stable vital signs on examination. The salient feature of a unilateral purulent rhinorrhoea succinctly suggested the possibility of an embedded foreign body. His facial examination did not show any sign of inflammation and the eye movements were normal. There was no saddle nose deformity observed. Subsequent investigation with a lateral view of the paranasal sinus radiograph unveiled a disc-shaped radio-opacity over the nasal cavity, which bore a resemblance of a button battery (figure 1).

An emergency endoscopic nasal examination under general anaesthesia was performed following informed consent. Intraoperatively, a huge posterior bony septal perforation was observed, through which the button battery embedded between the nasal cavities (figure 2). There was a spillage of corrosive content from the battery, thereby contributed to the surrounding nasal mucosa necrosis and inflammation (figure 3). The right middle turbinate and posterior part of right inferior turbinate were not identified, presumably eroded. The button battery was retrieved with an alligator forceps under scope guidance (figure 4). The surgical field was then thoroughly irrigated with copious amount of saline and diluted povidone solution (figure 5). The toddler was commenced with intravenous antibiotics and discharged well at day 2 after operation. He remained asymptomatic of septal perforation on further three monthly follow-ups.

DISCUSSION

The first reported case series of button batteries in the nasal cavity could be traced back in 1986.⁵ The most common age group



© Author(s) (or their employer(s)) 2019. Re-use permitted under CC BY-NC. No commercial re-use. See rights and permissions. Published by BMJ.

Otorhinolaryngology, Head and Neck Surgery, Hospital Selayang, Batu Caves, Malaysia

Correspondence to

Dr Geng Ju Tuang,
Otorhinolaryngology, Head
and Neck Surgery, Hospital
Selayang, Batu Caves 68100,
Malaysia; erictgj@gmail.com

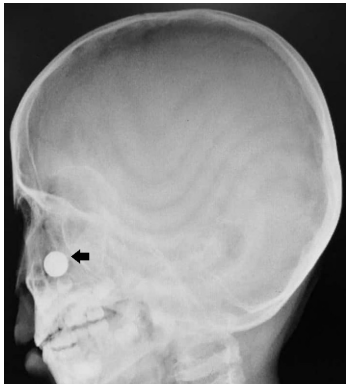


Figure 1 Lateral view of the paranasal cavity radiograph; a disc-shaped radio-opacity identified over the nasal region (arrow).

encountered in button battery ingestion ranged from 0 to 5 years old, with peak incidence between those aged 1 and 2 years old.² It is reported to have a slight male predominance with a ratio of 3:2.²

The signs and symptoms of an embedded foreign body in the nostril are often non-specific and tend to be overlooked by the treating physicians. This can be overcome by a detailed history taking and physical examination, which can crucially provide a clue as to an embedded foreign body. Clinicians should keep a high index of suspicion especially with children or intellectually challenged patients. Some of the red flags include a unilateral presentation, nasal pain and bloody discharge. On

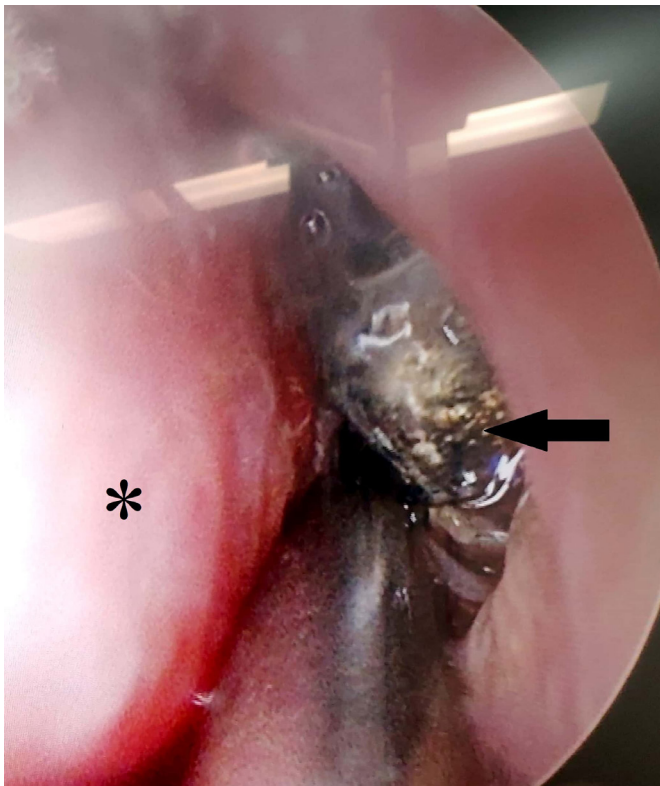


Figure 2 0° angled rigid endoscopic view of the right nasal cavity; right anterior part of inferior turbinate (*), embedded button battery (arrow).

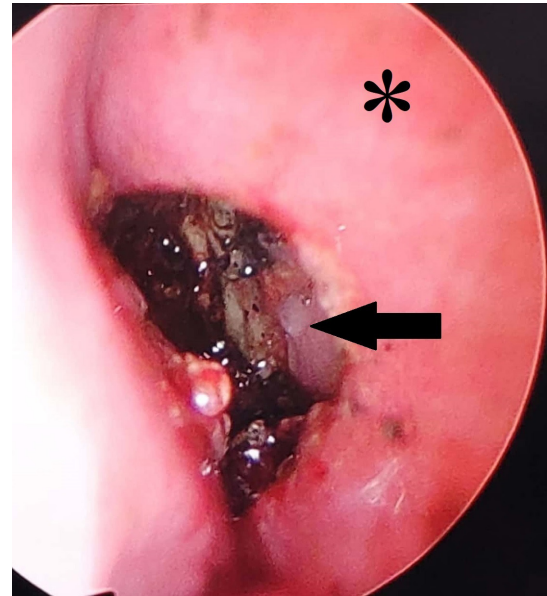


Figure 3 30° angled rigid endoscopic view of the right nasal cavity following the removal of button battery; nasal septum (*); huge perforation of the posterior nasal septum surrounded by necrotic nasal mucosa patches (arrow).

the other hand, rhinitis usually presents bilaterally with a history of atopy or recent sick contact. Nasal pain and bloody discharge often hint a diagnosis more sinister and warrant an immediate referral to the otorhinolaryngologist for further assessment.

On physical examination, clinicians should look meticulously for the presence of a foreign body, excessive unilateral nasal crusts and nasal mucosa ulceration. A cold spatula test can be easily performed to elicit unilateral nasal obstruction. A cold spatula is placed under

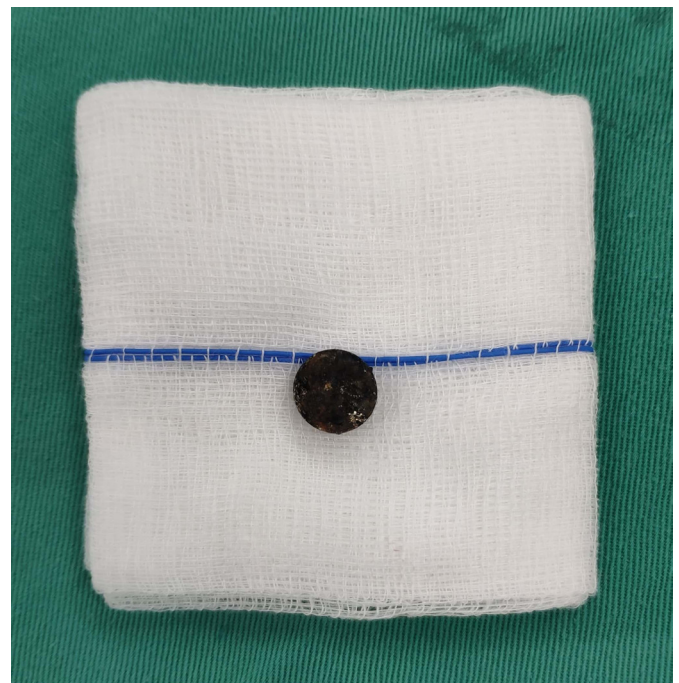


Figure 4 Button battery retrieved from the nasal cavity.

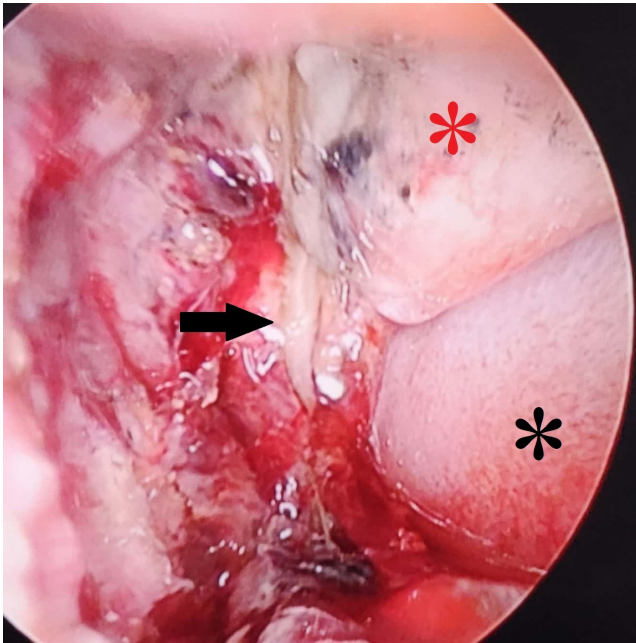


Figure 5 30° angled rigid endoscopic view of the posterior part of nasal cavity after irrigation; huge posterior septal perforation with part of exposed vomer bone (arrow), the right middle turbinate and posterior part of right inferior turbinate were not identified; left middle turbinate (* in red); left inferior turbinate (* in black).

the nostrils to compare the area of mist formation. The reduced or absence of mist formation from one nostril highly suggests of an embedded foreign body. An immediate referral for urgent intervention is of paramount particularly in a case of an embedded button battery.

X-ray of the paranasal sinus is highly recommended when in doubt. Button battery often displays a characteristic ‘double ring’ or ‘halo’ density, owing to the composition difference between its electrode plates and plastic grommet seal.⁴ A heterogeneous spectrum of sequela may result from an embedded button battery in the nasal cavity, varying from no complication to hazardous outcome such as septal perforation. The extent of injury is influenced by several factors such as the duration of mucosa exposure, the size, location, remaining voltage and chemical composition of the battery.^{2,5} Nasal mucosa injury ensues as early as 3 hours following an embedded button battery.⁴⁻⁶ The extent of injury is proportionate to the exposed time, with reported worsening of mucosa necrosis and septal perforation within 24 hours of exposure.^{4,7,8} Four proposed mechanisms accounted to mucosa injury include (1) pressure necrosis, (2) sodium hydrocyte leakage from the battery content, (3) electrical

discharge, and (4) toxic heavy metal absorption.^{2,4,7} The risk of secondary infections involving the regional structures includes sinusitis, periorbital cellulitis, otitis media and meningitis. If left untreated, sepsis may progress and result in fatal toxic shock syndrome.⁹ Consequently, timely removal of the button battery followed with generous irrigation of the nasal cavity is thus vital in order to eradicate the precipitate.

In conclusion, button battery in the nasal cavity represents an otorhinolaryngology emergency for its conceivable catastrophic sequela. The clinical presentation of unilateral nasal discharge in children should never be taken lightly. Foreign body should always be kept in mind for the differential diagnosis of unilateral rhinorrhoea for all general practitioners. Vigilant clinical assessment must be carried out and referral to the otorhinolaryngologist should be made to prevent complication.

Contributors All authors substantially contributed to conception or design of the case reports. GJT is the corresponding author, who was involved in drafting the case reports. NRNH and ZAZA were involved in revising the manuscript. All authors have approved the final version prior to submission.

Funding The authors have not declared a specific grant for this research from any funding agency in the public, commercial or not-for-profit sectors.

Competing interests None declared.

Patient consent for publication Parental/Guardian consent obtained.

Provenance and peer review Not commissioned; externally peer reviewed.

Open access This is an open access article distributed in accordance with the Creative Commons Attribution Non Commercial (CC BY-NC 4.0) license, which permits others to distribute, remix, adapt, build upon this work non-commercially, and license their derivative works on different terms, provided the original work is properly cited, appropriate credit is given, any changes made indicated, and the use is non-commercial. See: <http://creativecommons.org/licenses/by-nc/4.0/>.

REFERENCES

1. Dire DJ. Disk battery ingestion. *eMedicine* 2015.
2. Soni JP, Choudhary S, Sharma P, et al. Pneumopericardium due to ingestion of button battery. *Ann Pediatr Cardiol* 2016;9:94–5.
3. Littlehales E, Levi E, Mills N, et al. Double button battery ingestion – The “macaroon” sign. *J Pediatr Surg Case Rep* 2018;36:36–9.
4. Panda P, Raghavan D. Management of alkaline button battery foreign body in the nasal cavity at a peripheral centre. *Journal of Marine Medical Society* 2015;17:137–40.
5. Kaur J, Vijayashree MS, Borlingegowda V. An interesting case of button battery causing septal perforation. *Research in Otolaryngology* 2014;3:89–91.
6. Kadhimi NI, Alwan AA, Hadi I. Complications of button battery in the nose and preventions in Karbala. *Int J Pharm Pharm Res* 2017;9:282–7.
7. Watanabe K-ichi, Hatano G-ya, Aoki H, et al. The necessity of simple x-ray examination. *Pediatric Emergency Care* 2013;29:209–11.
8. Ramasamy V, Nadarajah S. The hazards of impacted alkaline battery in the nose. *J Family Med Prim Care* 2018;7:1083–5.
9. Abou-Elfadl M, Horra A, Abada R-L, et al. Nasal foreign bodies: results of a study of 260 cases. *Eur Ann Otorhinolaryngol Head Neck Dis* 2015;132:343–6.